

Endoscopic denervation of the wrist : anatomic feasibility and clinical outcomes

HYPOTHESIS

Concerning wrist surgery, arthroscopic procedures have increased their indications, but not yet for the denervation technique, which is a common and useful procedure^{1,2,3,4} ; performed alone or associated with an other wrist procedure^{5,6}.

Our objectives were to evaluate, in an anatomic study, the feasibility and safety of an arthroscopic selective denervation of the wrist ; then, to assess its efficiency in a clinical prospective series.

METHOD

Cadaveric lab : 5 specimens were operated on both sides (n=10). We used a 1,9mm arthroscope with 35mmHg pump pressure, 2&3mm shaver blades ; 2 dorsal portals, (one ulnar, one radial) located on the same line 2,5cm proximal to the Lister's tubercle⁷. Under arthroscopy, we performed an identification and excision of the posterior interosseous nerve and also the anterior interosseous nerve through the interosseous membrane⁸, followed by a periosteal excision of the dorsal part of the radius and cubitus. We secondly performed an open control to assess the efficiency and safety.

Prospective clinical series : 14 patients were included: 11 arthritis^{6,9} (5 SNAC, 4 SLAC, 2 post-radius fracture arthritis), 1 Kienbock'desease¹⁰ , and 2 midcarpal instabilities¹¹. The arthroscopic denervation was always associated with a synovial arthroscopic wrist debridement (4 styloidectomies, 1 ossification excision, 3 ligament shrinking and 6 debridement only). The articular arthroscopy was performed first, then the selective denervation.

Clinical examinations with DASH and Mayo Wrist Score were performed pre-operatively and post-operatively.

RESULTS

Cadaveric (n=10) :

-Efficiency criteria: a 8mm-length excision of both interosseous nerves was possible in all cases. The periosteal excision was continuous with a transversal 6mm-width strip for all.

-Safety : none morbidity on extensors or radial branches was reported.

Per-operative (n=14) : the average duration was 24 min (18-35) for the denervation and 42 min (15-98) for the articular arthroscopy, identification and excision of the two interosseous nerves were performed in all cases

Clinical outcomes (n=14) :

-Efficiency : MayoWristScore went from 15 preop to 60 postop, DASH went from 65 preop to 36 postop.

-Safety : none tendinous or sensitive skin disorders was observed.

SUMMARY POINTS

This study confirmed the feasibility and safety of an endoscopic selective denervation.

Efficiency is present but further investigations are needed to determine which part of the efficiency is due to the intra-articular wrist surgery or to the selective denervation.

A selective endoscopic denervation of both interosseous nerves can be associated with various types of arthroscopic surgery, which extends the therapeutic arsenal of wrist arthroscopy.

PHOTOS :

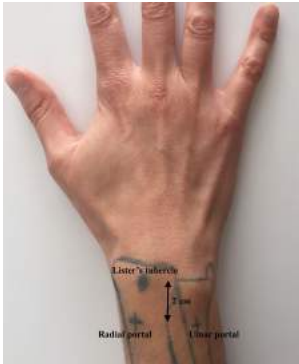

Photo 1 : Landmarks and portals

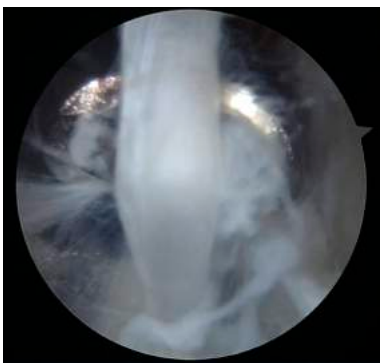


Photo 2 : Posterior *interosseous nerve before excision with a 2mm-shaver blade*

BIBLIOGRAPHY

1. Wilhelm A. [DENERVATION OF THE WRIST]. Hefte Unfallheilkd 1965;81:109-14.
2. Zimmermann I, Kubatov M, Renner A, Viola T. [Selective denervation of the wrist joint]. Magy Traumatol Orthop És Helyreállítás Seb 1991;34(3):181-6.
3. Foucher G, Da Silva JB, Ferreres A. [Total denervation of the wrist. Apropos of 50 cases]. Rev Chir Orthopédique Réparatrice Appar Mot 1992;78(3):186-90.
4. Ishida O, Tsai TM, Atasoy E. Long-term results of denervation of the wrist joint for chronic wrist pain. J Hand Surg Edinb Scotl 1993;18(1):76-80.
5. Ferreres A, Suso S, Foucher G, Ordi J, Llusà M, Ruano D. Wrist denervation. Surgical considerations. J Hand Surg Edinb Scotl 1995;20(6):769-72.
6. Rothe M, Rudolf K-D, Partecke B-D. [Long-term results following denervation of the wrist in patients with stages II and III SLAC-/SNAC-wrist]. Handchir Mikrochir Plast Chir Organ Deutschsprachigen Arbeitsgemeinschaft Für Handchir Organ

Deutschsprachigen Arbeitsgemeinschaft Für Mikrochir Peripher Nerven Gefässe
Organ Ver Dtsch Plast Chir 2006;38(4):261–6.

7. Jariwala A, Krishnan B, Soames R, Wigderowitz CA. Important anatomical relationships of the posterior interosseous nerve in the distal forearm for surgical planning: a cadaveric study. J Wrist Surg 2014;3(1):60–3.
8. Berger RA. Partial denervation of the wrist: a new approach. Tech Hand Up Extrem Surg 1998;2(1):25–35.
9. Hohendorff B, Mühldorfer-Fodor M, Kalb K, von Schoonhoven J, Prommersberger K-J. [Long-term results following denervation of the wrist]. Unfallchirurg 2012;115(4):343–52.
10. Buck-Gramcko D. Wrist denervation procedures in the treatment of Kienböck's disease. Hand Clin 1993;9(3):517–20.
11. Hofmeister EP, Moran SL, Shin AY. Anterior and posterior interosseous neurectomy for the treatment of chronic dynamic instability of the wrist. Hand N Y N 2006;1(2):63–70.

DISCUSSION

Before this work, in our experience of wrist arthritis, , we used to perform two different kinds of procedures :

- either we performed an arthroscopic palliative surgery inside the wrist (resurfacing, styloidectomy, osteophyte excisions, partial arthrodesis) BUT we didn't associate a denervation because we didn't want to lose the benefits of the arthroscopic procedure with the drawbacks of an open surgery of denervation.

-or we performed a full denervation of the wrist in open surgery with many incisions BUT we didn't open the joint because we feared stiffness by opening the wrist capsule.

The goal of this work was to gather the benefits of the denervation and the benefits of wrist arthroscopy in order to act at the origin of the pain (inside the joint) and on the conduction of the pain (denervation).